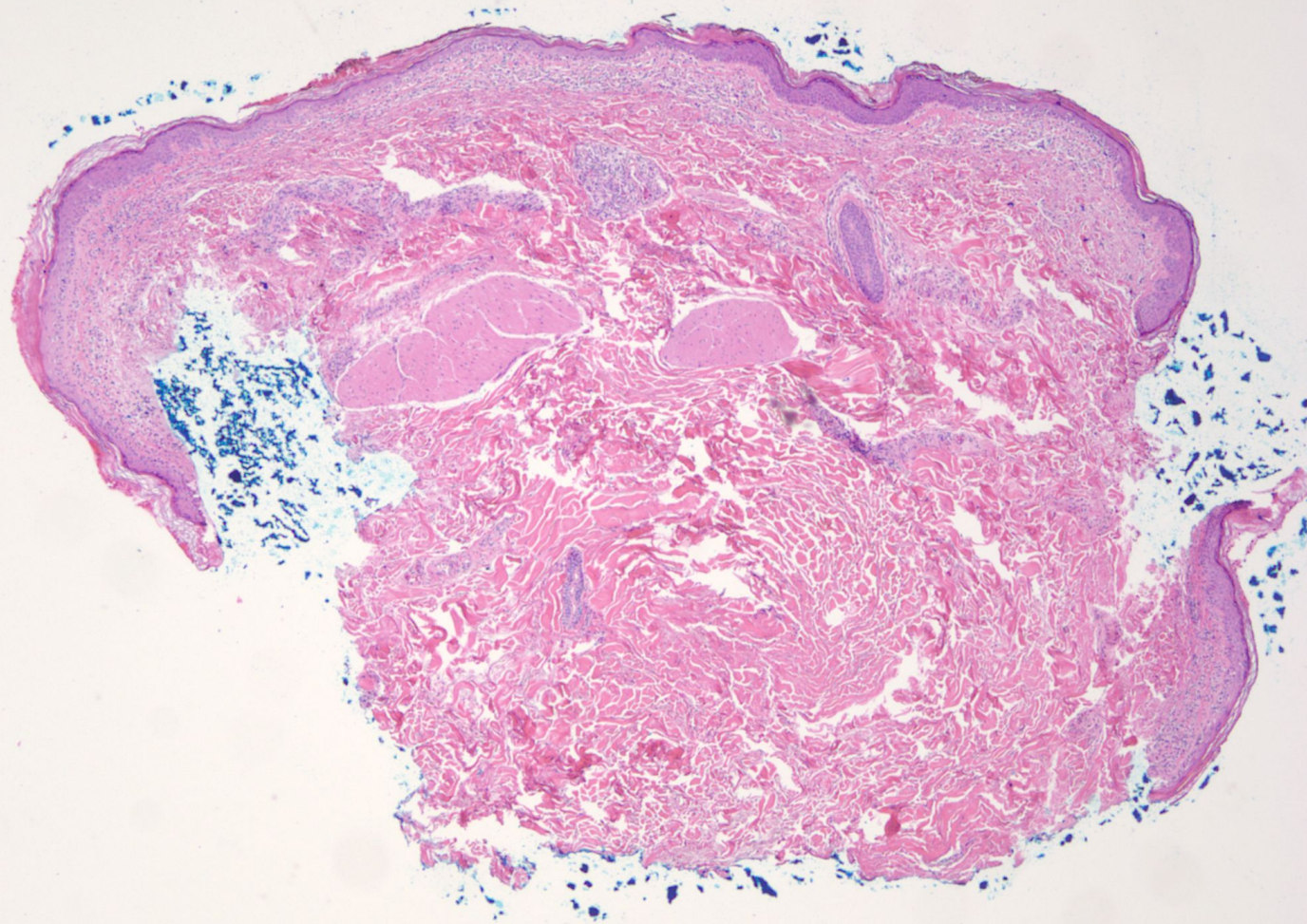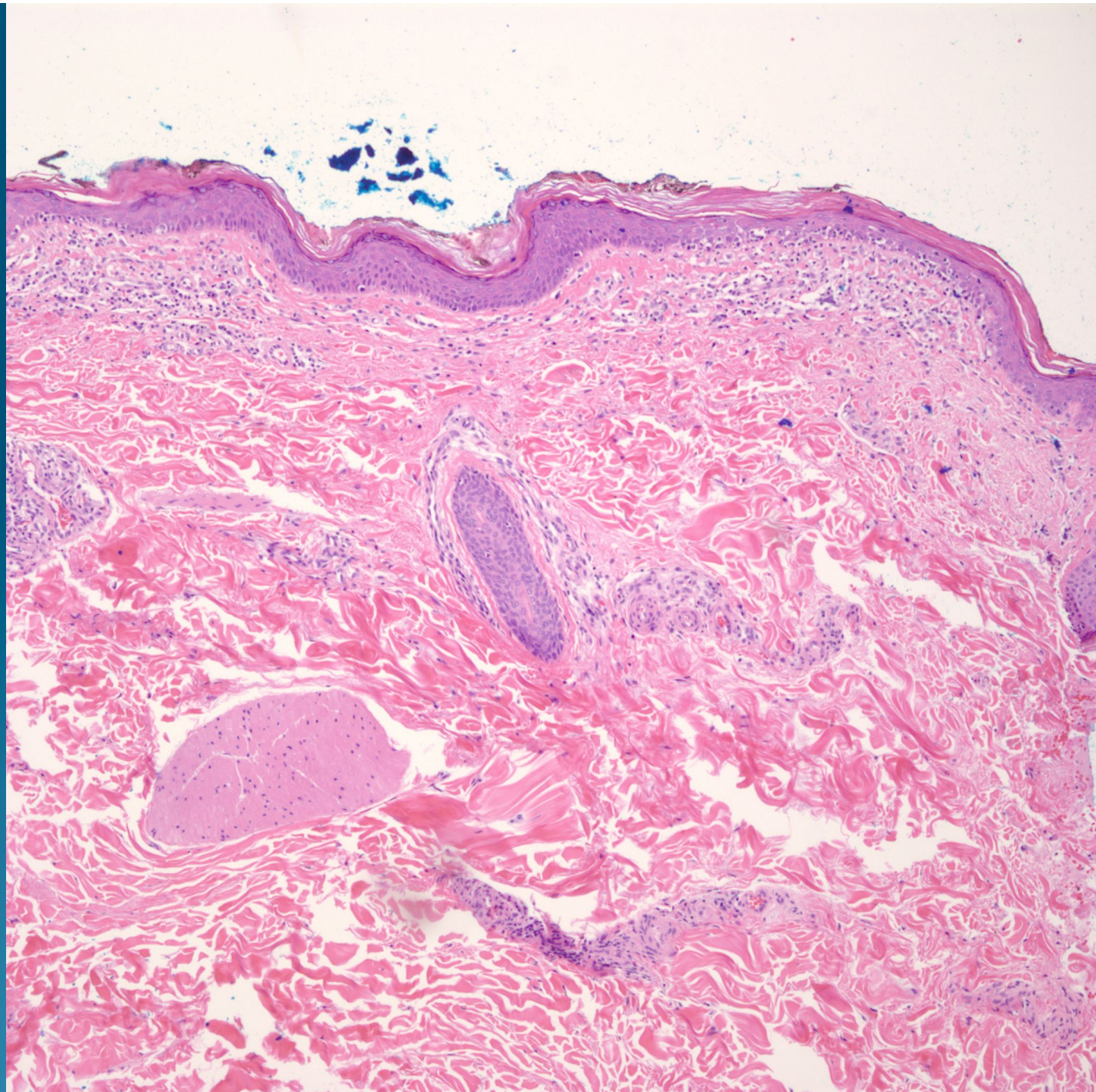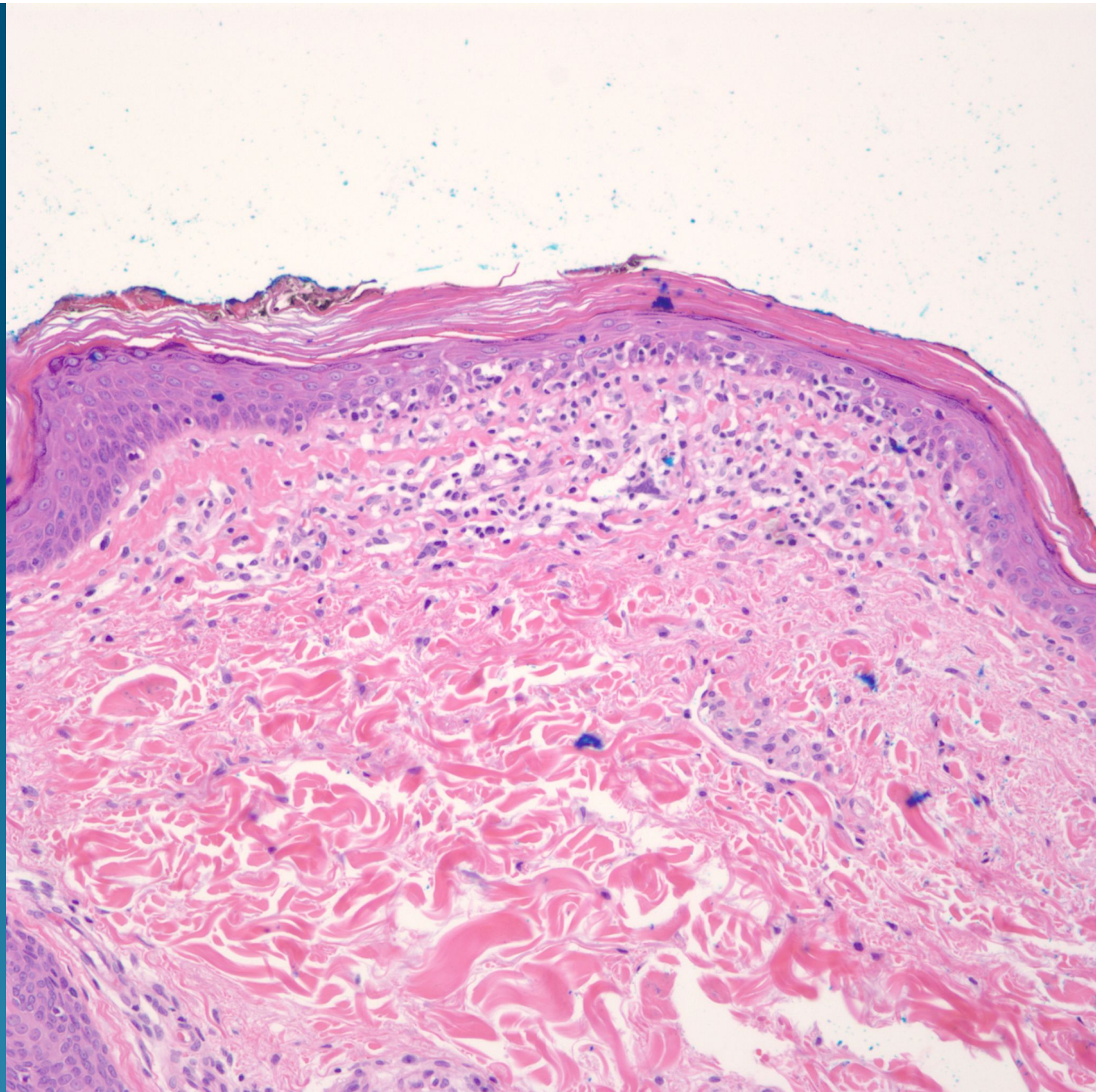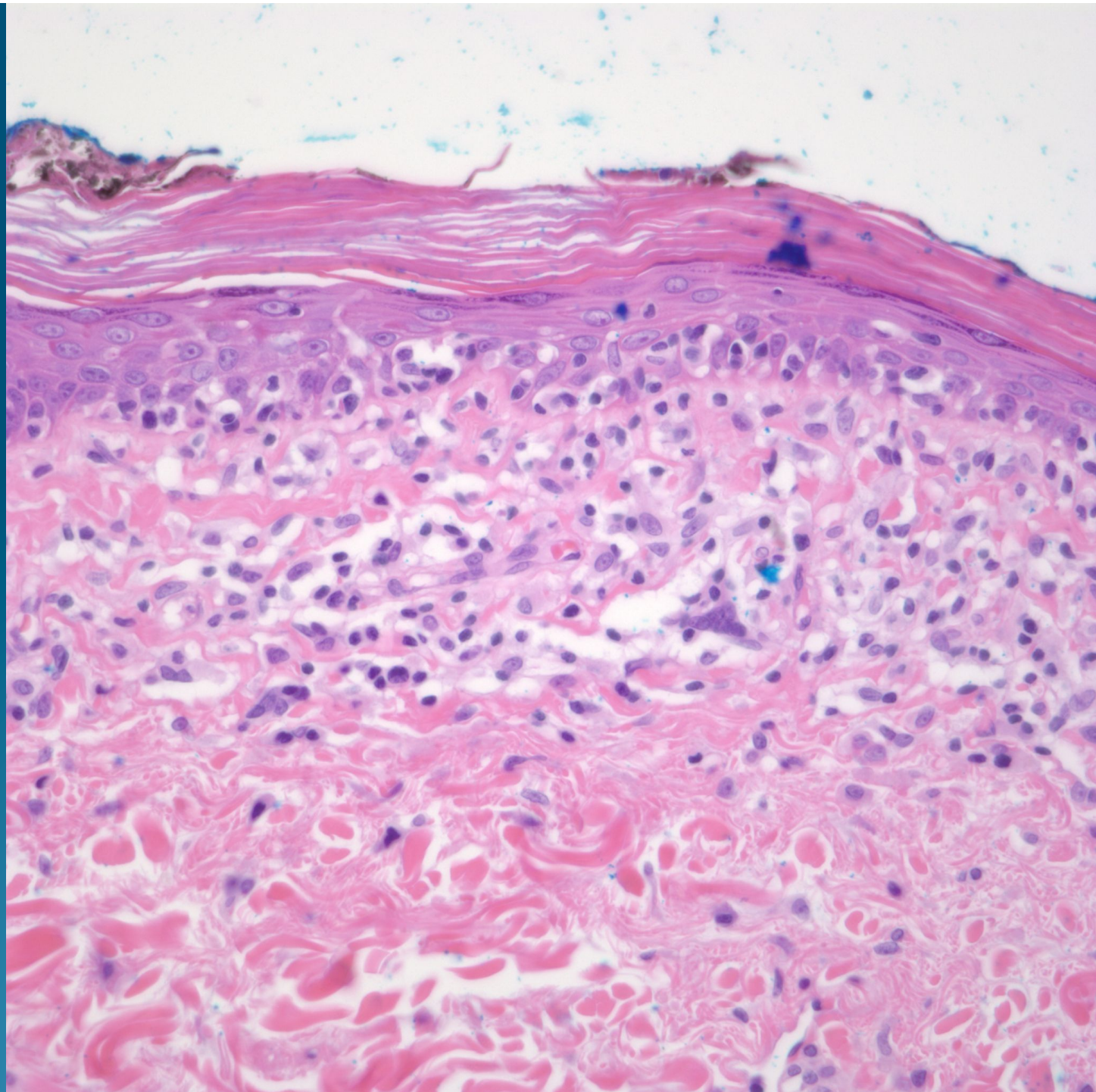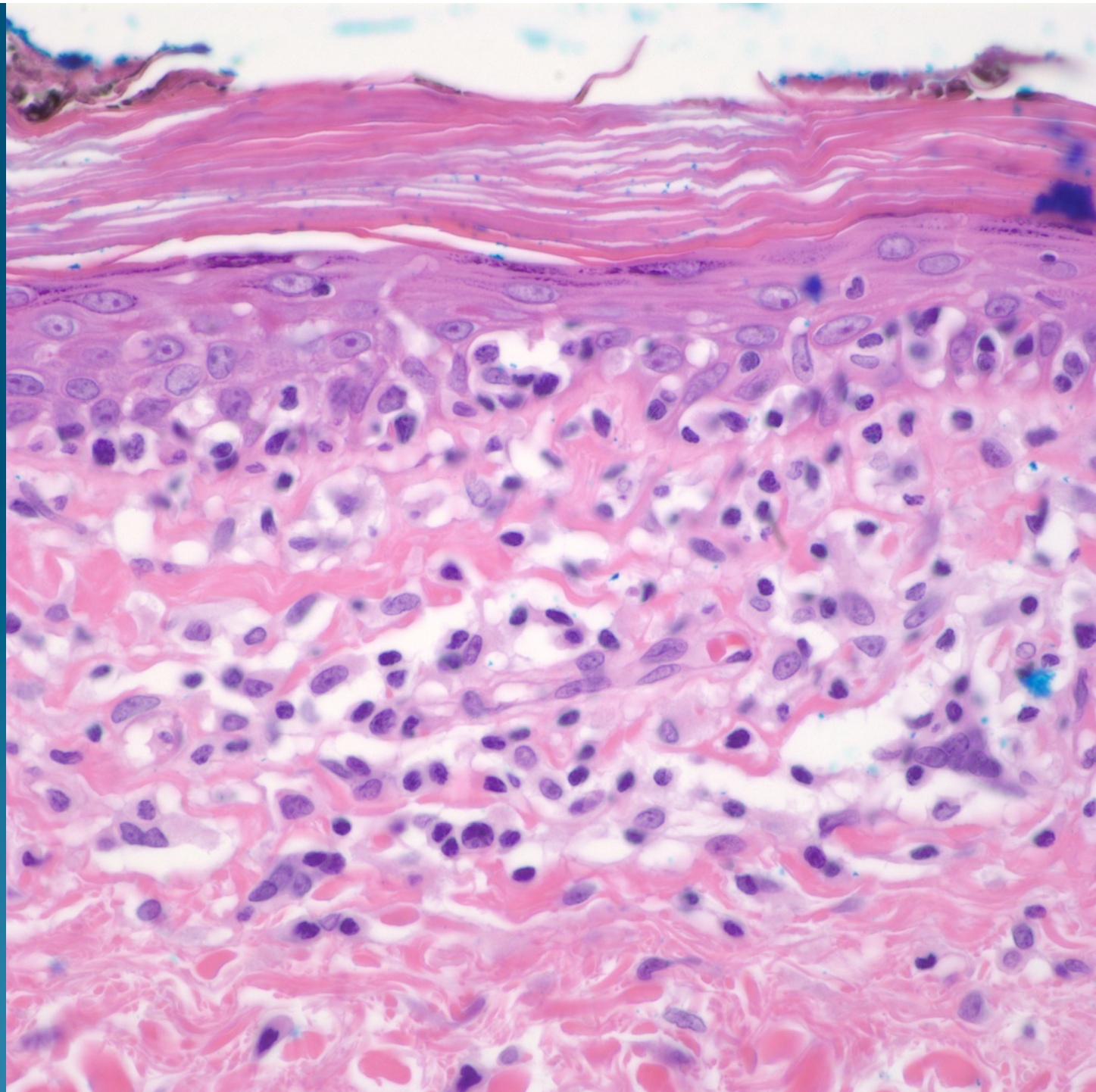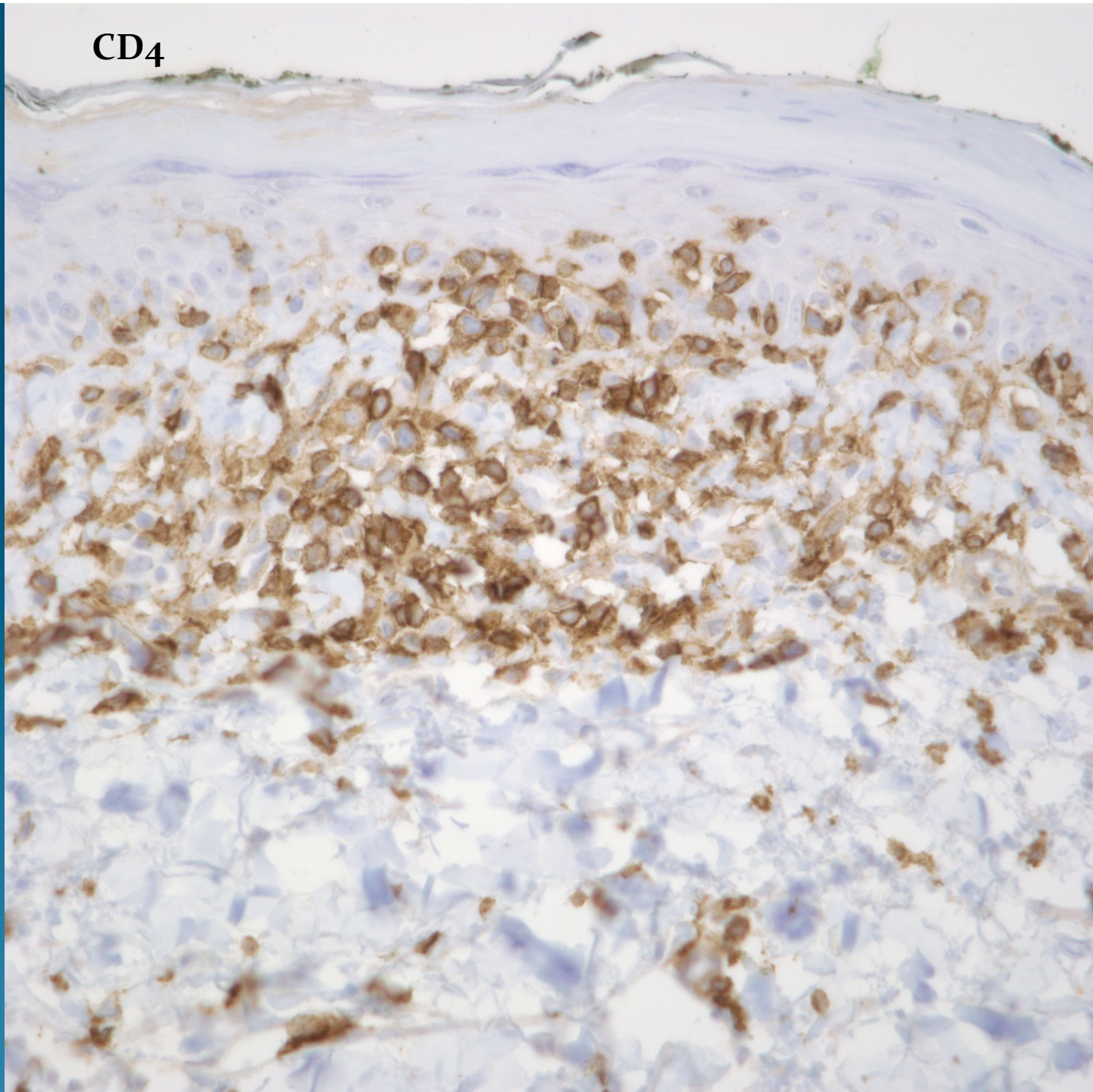


What is the best diagnosis?

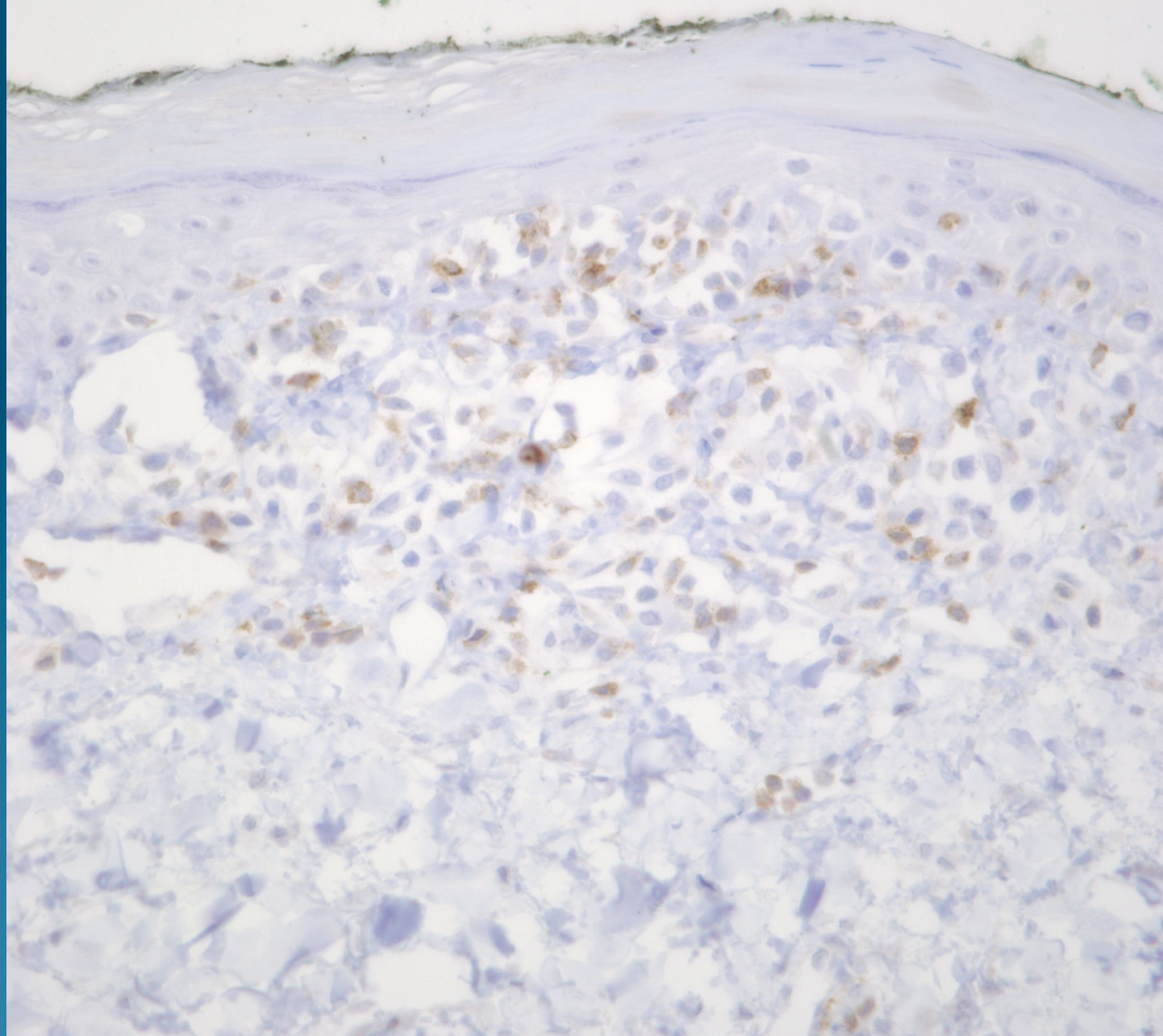
- A. Erythema multiforme
- B. Lymphomatoid papulosis
- C. Graft versus host disease
- D. Mycosis fungoides
- E. Anaplastic large cell lymphoma

Mycosis fungoides

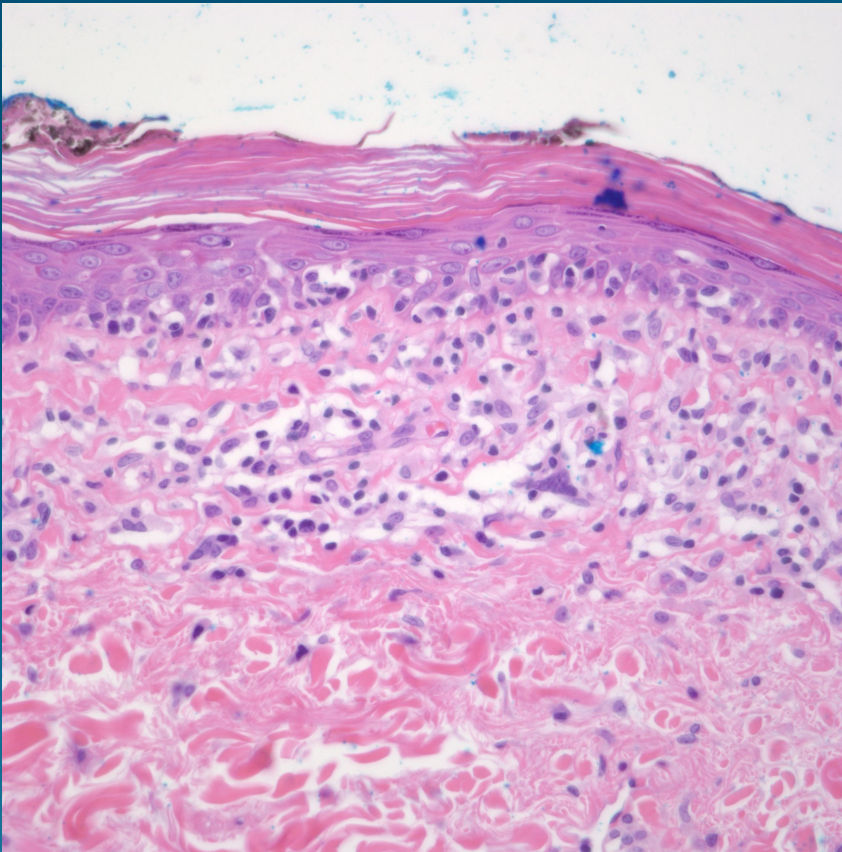
CD4



CD7



Pearls



- Intraepidermal proliferation of atypical lymphocytes with hyperchromatic and hyperconvoluted nuclear contours
- Intercalation with basal keratinocytes
- Pautrier microabscesses with minimal spongiosis
- Most common immunophenotype CD4+/CD7-
- Rule out lymphomatoid drug eruptions